






RESEARCH ARTICLE

Squamous differentiation portends poor prognosis in low and intermediate-risk endometrioid endometrial cancer

Diocesio Alves Pinto de Andrade^{1,2}^{*}, Vinicius Duval da Silva³[☉], Graziela de Macedo Matsushita³[‡], Marcos Alves de Lima⁴[‡], Marcelo de Andrade Vieira⁵[‡], Carlos Eduardo Mattos Cunha Andrade⁵[‡], Ronaldo Luís Schmidt⁵[‡], Rui Manuel Reis^{2,6,7}[☉], Ricardo dos Reis⁵[☉]

1 Department of Oncology, InORP ONCOCLÍNICAS Group (Oncology Institute of Ribeirão Preto), Ribeirão Preto, São Paulo, Brazil, **2** Molecular Oncology Research Center, Barretos Cancer Hospital, Barretos, São Paulo, Brazil, **3** Department of Pathology, Barretos Cancer Hospital, Barretos, São Paulo, Brazil, **4** Epidemiology and Biostatistics Nucleus, Barretos Cancer Hospital, Barretos, São Paulo, Brazil, **5** Department of Gynecologic Oncology, Barretos Cancer Hospital, Barretos, São Paulo, Brazil, **6** Life and Health Sciences Research Institute (ICVS), School of Medicine, University of Minho, Braga, Portugal, **7** ICVS/3B's - PT Government Associate Laboratory, Braga/Guimarães, Portugal

 These authors contributed equally to this work.

[‡] These authors also contributed equally to this work.

^{*} diocesio@yahoo.com



OPEN ACCESS

Citation: Andrade DAPd, da Silva VD, Matsushita GdM, de Lima MA, Vieira MdA, Andrade CEMC, et al. (2019) Squamous differentiation portends poor prognosis in low and intermediate-risk endometrioid endometrial cancer. PLoS ONE 14 (10): e0220086. <https://doi.org/10.1371/journal.pone.0220086>

Editor: Nicola Silvestris, Cancer Institute, ITALY

Received: June 30, 2019

Accepted: September 23, 2019

Published: October 10, 2019

Copyright: © 2019 Andrade et al. This is an open access article distributed under the terms of the [Creative Commons Attribution License](https://creativecommons.org/licenses/by/4.0/), which permits unrestricted use, distribution, and reproduction in any medium, provided the original author and source are credited.

Data Availability Statement: All relevant data are within the manuscript and its Supporting Information files.

Funding: The author(s) received no specific funding for this work.

Competing interests: The authors have declared that no competing interests exist.

Abstract

Background

Endometrial cancer presents well-defined risk factors: myometrial invasion, histological subtype, tumor grade, lymphovascular space invasion (LVSI). Some low and intermediate-risk endometrioid endometrial cancer patients exhibited unexpected outcomes. This study aimed to investigate other clinical-pathological factors that might influence the recurrence rates of patients diagnosed with low and intermediate-risk endometrioid endometrial cancer.

Methods

A case-control study from a cohort retrospective of 196 patients diagnosed with low and intermediate-risk endometrioid endometrial cancer at a single institution from 2009 to 2014 was conducted. Medical records were reviewed to compare clinical (race, smoking, menopause age, body mass index) and pathological (endometrioid vs endometrioid with squamous differentiation, tumor differentiation grade, tumor location, endocervical invasion, LVSI) features of patients with recurrence (case) and without recurrence (control) of disease. Three controls for each case were matched for age and staging.

Results

Twenty-one patients with recurrence were found (10.7%), of which 14 were stage IA, and 7 were stage IB. In accordance, 63 patients without recurrence were selected as controls. There were no significant differences in any clinical characteristics between cases and controls. Among pathological variables, presence of squamous differentiation (28.6% vs. 4.8%,

$p = 0.007$), tumor differentiation grade 2 or 3 (57.1% vs. 30.2%, $p = 0.037$) and presence of endocervical invasion (28.6% vs. 12.7%, $p = 0.103$) were associated with disease recurrence on a univariate analysis. On multivariable analysis, only squamous differentiation was a significant risk factor for recurrence ($p = 0.031$).

Conclusion

Our data suggest that squamous differentiation may be an adverse prognostic factor in patients with low and intermediate-risk endometrioid endometrial cancer, that showed a 5.6-fold increased risk for recurrence.

Introduction

Endometrial cancer is the most prevalent gynecological neoplasia in women in the US, accounting for more than 63,000 cases/year and with a lethality rate close to 18%.^[1] In Brazil, this tumor represents the second most common cause of gynecological cancer due to a high incidence of cervix tumors.^[2] Despite knowledge advances related to genetic alterations of this neoplasia in the last few years, classification of endometrial cancer into type I (endometrioid) or type II (serous or clear cell) continues to be used in clinical practice, mainly to evaluate risk factors in tumor progression.^[3]

As in other solid tumors, staging of endometrial cancer is important to define surgical extension, ranging from hysterectomy with bilateral salpingo-oophorectomy to a pelvic and/or para-aortic lymphadenectomy.^[4] Risk stratification in stage I tumors aims to assess the risk of lymph node involvement, the recurrence pattern, patient's prognosis and the best adjuvant treatment to be performed.^[5] Beyond myometrial tumor invasion depth, other clinical-pathological factors have been evaluated: age; histological subtype; tumor differentiation grade and lymphovascular space invasion (LVSI).^[6,7] Besides these features, other immunohistochemistry markers, such as L1-cell adhesion molecule (L1CAM) and p53, are also associated with patient outcome for stage I endometrial cancer, but not yet incorporated in current classifications.^[8,9]

Endometrial adenocarcinoma with squamous differentiation terminology was defined by Zaino and Kurman in 1988 to replace two previously used nomenclature for uterus neoplasms: adenoacanthoma and adenosquamous carcinoma.^[10] Squamous differentiation consists of sheets of cells with intercellular bridges and prominent cell membranes with or without keratinization.^[11] It is present in about 13–25% of endometrial adenocarcinomas.^[10,12] The finding of squamous differentiation in the anatomopathological examination remains controversial as a risk factor for recurrence in patients with early-stage endometrial cancer.^[13,14]

The aim of this study was to evaluate clinical-pathological features that influenced the recurrence of patients diagnosed with low and intermediate-risk endometrial cancer, according to the ESMO (European Society for Medical Oncology) criteria.^[5]

Patients and methods

A case-control study nested in a retrospective cohort of 196 patients diagnosed with low and intermediate-risk endometrial cancer undergoing surgery at Barretos Cancer Hospital from January 2009 to December 2014 was conducted. This study was held in accordance with the

principles of the Declaration of Helsinki and it was previously approved by the Ethical Review Board from Barretos Cancer Hospital in March 2017 (Reference 1.942.488). Cases were defined as patients who presented systemic or locoregional recurrence at any time of their follow-up. We defined three controls for each recurrence case, matching age (± 1 year) and FIGO (International Federation of Gynecology and Obstetrics) staging (IA and IB).

According to ESMO criteria[5], low-risk endometrial cancer is defined as endometrioid adenocarcinoma stage IA grade 1 or grade 2; intermediate-risk endometrial cancer is defined as endometrioid adenocarcinoma stage IA grade 3 or endometrioid adenocarcinoma stage IB grade 1 or grade 2. Three or more of the following four criteria need to be present to define squamous differentiation: sheet-like growth without glands or palisading, sharp cells margins, eosinophilic and thick of glassy cytoplasm, and decreased nuclear-to-cytoplasmic ratio compared with foci elsewhere in the same tumor.[11] The amount of squamous differentiation can vary and in a well-sampled carcinoma the squamous differentiation should comprise at least 10% of the neoplasia. The degree of nuclear atypia, if present, generally reflects that of the glandular cells.[15]

Clinical-pathological data were reviewed from medical records. The diagnoses of low and intermediate-risk endometrial cancer were confirmed by the surgical histopathologic report. Patients who did not perform definitive surgical treatment at the institution (for example, patients who underwent surgery at their region of origin and who were referred to a tertiary hospital only for adjuvant treatment) were excluded.

The following clinical-pathological criteria were evaluated: ECOG (Eastern Cooperative Oncology Group) scale of performance status (0–1 vs 2); race/ethnicity (white vs non-white); body mass index (BMI); hormonal status (menopause vs menacme); number of pregnancies; smoking (yes vs no); tumor differentiation grade (1, 2 or 3); histological characteristics (endometrioid vs endometrioid with squamous differentiation); tumor size; tumor location (uterine corpus vs lower uterine segment); endocervical invasion (yes vs no) and LVSI (yes vs no).

Statistical analysis

Both the data collected and analyses were performed using IBM Statistical Package for the Social Sciences (SPSS) database version 21.0 (SPSS, Chicago, IL). Descriptive statistical analysis used median, maximum and minimum value for quantitative variables and percentage for qualitative variables. Once the above variables were defined, univariate analysis was performed using Mann-Whitney's U-test or Fisher's exact test. Parameters with $P < 0.2$ in univariate analyses were entered into the logistic regression analysis. Backward stepwise logistic regression models were constructed. The comparisons were considered statistically significant at $P < 0.05$. Study data were collected and managed using REDCap (Research Electronic Data Capture), electronic data capture tools hosted at Barretos Cancer Hospital.[16]

Results

Of the 196 endometrial cancer patients described in this retrospective cohort, 21 patients (10.7%) presented recurrence during their evolution (cases), of which 2/3 were stage IA and 1/3 were stage IB, and 63 patients without recurrence were selected as controls (Table 1). The median age of both groups was 64 years and both groups also exhibit a similar fraction of IA staging. Moreover, the patient population was obese (median BMI above 30), white and non-smoker (Table 1). Almost all patients were already in menopause (11.2% of controls were still in menacme).

Standard hysterectomy with bilateral salpingo-oophorectomy was carried out in 44.4% of controls and 57.1% cases; pelvic systematic lymphadenectomy was done in 28.6% of controls

Table 1. Univariate analysis of predictive recurrence for low and intermediate-risk endometrioid endometrial cancer.

		Case (n = 21)	Control (n = 63)	P-value
Age (median) ^a		64 (46–77)	64 (46–78)	0.873
FIGO staging (%) ^b	IA	14 (66.7)	42 (66.7)	>0.99
	IB	7 (33.3)	21 (33.3)	
ECOG Performance Status (%) ^b	0–1	20 (95.2)	61 (96.8)	>0.99
	2	1 (4.8)	2 (3.2)	
Race/Ethnicity (%) ^b	White	18 (85.7)	45 (71.4)	0.251
	Non-white	3 (14.3)	18 (28.6)	
BMI (median) ^a		31.64 (19.78–48.62)	32.65 (21.93–52.71)	0.339
Smoking history ^b	Yes	2 (9.5)	4 (6.3)	0.637
	No	19 (90.5)	59 (93.7)	
Menopause (%) ^b	Yes	21	56 (88.8)	0.184
	No	0	7 (11.2)	
Number of pregnancies (median) ^a		4 (1–7)	4 (1–20)	0.725
Tumor differentiation grade ^b	Grade 1	9 (42.9)	44 (69.8)	0.037
	Grade 2 or 3	12 (57.1)	19 (30.2)	
Histological subtype (%) ^b	Endometrioid	15 (71.4)	60 (95.2)	0.007
	Endometrioid with squamous differentiation	6 (28.6)	3 (4.8)	
Tumor size (median–cm) ^a		4.0 (16.0–115.0)	4.0 (1.0–105.0)	0.597
Tumor localization ^b	Uterine corpus	14 (66.7)	47 (74.6)	0.574
	Lower uterine segment	7 (33.3)	16 (25.4)	
Endocervical invasion (%) ^b	Yes	6 (28.6)	8 (12.7)	0.103
	No	15 (71.4)	55 (87.3)	
LVSI (%) ^b	Yes	5 (23.8)	9 (14.3)	0.324
	No	16 (76.2)	54 (85.7)	

BMI–body mass index; ECOG–Eastern Cooperative Oncology Group; FIGO–International Federation of Gynecology and Obstetrics; LVSI–lymphovascular space invasion.

^a—Mann-Whitney test;

^b—Fisher’s exact test

<https://doi.org/10.1371/journal.pone.0220086.t001>

and 9.5% of cases; retroperitoneal and pelvic lymphadenectomy was performed in 22.2% of controls and 28.6% of cases, since there was no statistical difference between the groups ($p 0.38$). Lymph node staging was performed in 52.4% of controls and 38.1% of cases, without a statistical difference ($p 0.26$).

Adjuvant radiotherapy was performed in 85.7% of controls and 76.2% of cases. Of these, 76.2% of controls and 66.7% of cases received only brachytherapy, without a statistical difference ($p 0.68$).

Squamous differentiation appears as solid areas in the middle of glandular tissue. These areas, although solid, cannot be considered as such for grading purpose (Fig 1a and 1b). A specific immunohistochemical marker used to evaluate squamous lineage is p63, as shown in the inset (Fig 1c).[17]

There were no significant differences regarding race/ethnicity, ECOG performance status, number of pregnancies, smoking history, tumor size, tumor localization and LVSI between the group of patients with recurrence (cases) and the group of patients without recurrence (controls) (Table 1).

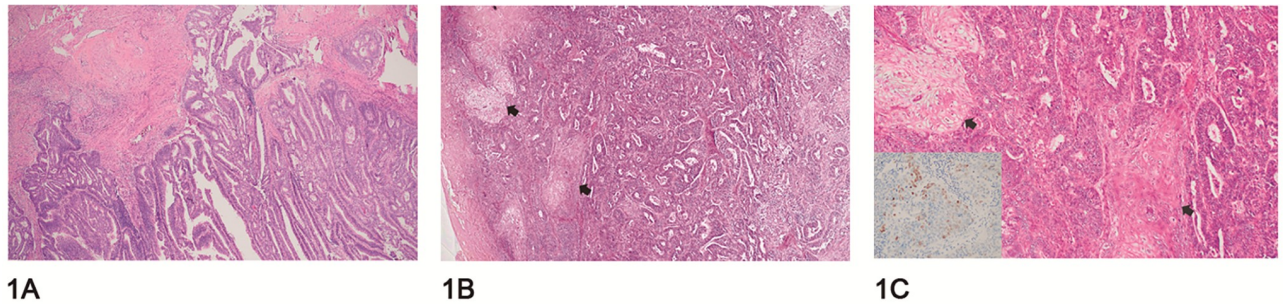


Fig 1. Histopathological difference between endometrioid adenocarcinoma with and without squamous transformation. (A) Depicts an endometrioid adenocarcinoma without squamous transformation. (B) Shows a case with squamous transformation areas highlighted with arrows. (C) Highlights the squamous transformation areas at a higher magnification (arrows). The inset presents nuclear p63 positivity, a protein antibody used to demonstrate squamous differentiation by immunohistochemistry in a squamous transformation area.

<https://doi.org/10.1371/journal.pone.0220086.g001>

In the univariate analysis, four parameters with $P < 0.2$ were chosen for the multivariate logistic regression analysis: hormonal status (menopause), tumor differentiation grade, histological characteristics and endocervical invasion (Table 1). The variable ‘menopause’ had to be withdrawn from this model since one of its categories did not present participants (no menopause in case group), resulting in a no data conversion to the odds ratio value. Using backward stepwise logistic regression technique, a new model was constructed with three parameters: histological subtype with squamous differentiation (28.6% vs. 4.8%, $p = 0.007$), tumor differentiation grade 2 or 3 (57.1% vs. 30.2%, $p = 0.037$) and presence of endocervical invasion (28.6% vs. 12.7%, $p = 0.103$) (Table 1).

In multivariate analysis, only histological subtype (endometrioid vs endometrioid with squamous differentiation) was associated with recurrence ($p = 0.031$) (Table 2). Women who presented squamous differentiation associated with classic endometrioid subtype had a 5.6-fold increased risk for recurrence when compared to the group that does not show this histological finding (Table 2).

Discussion

This case-control study of low and intermediate-risk endometrial cancer demonstrated that patients with endometrioid squamous differentiation subtype had a greater chance of recurrence when compared to patients with typical endometrioid histological subtype. This finding in the anatomopathological examination remains controversial as a risk factor for recurrence as published in the international literature (Table 3).

Table 2. Multivariate analysis of predictive recurrence for low and intermediate-risk endometrioid endometrial cancer.

		Odds Ratio (IC- 95%)	P-value
Tumor differentiation grade	Grade 1	1	0.080
	Grade 2 or 3	2.66 (0.89–7.96)	
Tumor type	Endometrioid	1	0.031
	Endometrioid with squamous differentiation	5.65 (1.17–27.17)	
Endocervical invasion	No	1	0.168
	Yes	2.55 (0.67–9.66)	

Constant = -1.939 ($P = 0.0001$)

<https://doi.org/10.1371/journal.pone.0220086.t002>

Table 3. Summary of squamous differentiation endometrioid endometrial cancer studies to predict recurrence.

References	Year	Country	N	Study design	Risk for recurrence
This study	2019	Brazil	84	Case-control	Yes
Misirlioglu <i>et al.</i> [13]	2012	Turkey	223	Case-control	Yes
Jiang <i>et al.</i> [21]	2017	China	630	Retrospective cohort	Yes
Zaino <i>et al.</i> [14]	1991	USA	631	Prospective cohort	No
Sturgeon <i>et al.</i> [22]	1998	USA	648	Case-control	No
Lax <i>et al.</i> [23]	1998	USA	77	Case series	Variable
Abeler <i>et al.</i> [12]	1992	Norway	255	Retrospective cohort	Variable

<https://doi.org/10.1371/journal.pone.0220086.t003>

FIGO staging classifies endometrial cancer grade into three groups: grade 1 tumors are those in which less than 5% of the neoplasm is arranged as solid growth; grade 2 tumors are those in which 5% to 50% of the neoplasms are arranged in solid sheets, and grade 3 tumors are those in which greater than 50% of the neoplasm form solid masses.[18] The current FIGO grade system, primarily based on the relative proportion of solid and glandular areas, also considers nuclear atypia, and grading is increased by one if more than 50% severe nuclear atypia (grade 3 nuclei) is found in the neoplastic glands.[19] Currently, squamous differentiation does not enter into this classification, although it can mimic solid tumors areas. It can be found in all forms of endometrial hyperplasia, being more common in atypical endometrial proliferation.[15] The squamous and glandular components have the same PTEN mutations, which indicates that they are clonally related.[20]

Some studies showed that squamous differentiation is a risk factor for endometrial cancer recurrence.[13,21] A retrospective study of 223 patients with early-stage endometrial cancer, carried out by Misirlioglu *et al.*, similar to our study, regarding methodological structure, showed squamous differentiation as a risk factor for recurrence in early-stage endometrial cancer.[13] The authors reported 10.31% of recurrence (23 cases), very similar to that found in our study. Several risk factors were considered positive to increase the chance of recurrence (age, depth of myometrial tumor invasion, tumor differentiation grade, lymphovascular space invasion, tumor localization, tumor size), including squamous differentiation, as in our results.[13] Another retrospective cohort with 630 patients with stage I endometrioid endometrial cancer conducted by Jiang *et al.* evaluated possible risk factors for metastasis in this tumor. Beyond traditional factors such as tumor size and depth of myometrial invasion, squamous differentiation was also an independent risk factor for the development of pulmonary metastasis.[21]

On the other hand, there are some studies showing that squamous differentiation does not pose a worse prognosis. A large study (n = 631) conducted by Gynecologic Oncology Group (GOG) in the late 1970s and early 1980s, evaluated the prognosis role of the patients with or without histological squamous differentiation.[14] Five-years overall survival was 90% for patients with squamous differentiation *versus* 82% for patients without this differentiation with statistical significance.¹⁴[14] A case-control study with 640 patients carried out by Sturgeon *et al.* showed that squamous differentiation is not a poor prognostic factor for patients diagnosed with endometrioid endometrial cancer.[22]

On account of conflicting results for defining prognosis of tumors, it may be necessary to classify the squamous differentiation component into low or high degree. An immunohistochemistry study of 77 patients evaluated estrogen (ER) receptor, progesterone (PR) receptor, p53 and Ki-67, reported that tumors with high-grade squamous differentiation (lack of expression of ER and PR; high Ki-67 index and p53 expression) have a worse outcome.[23] This controversy about the prognosis of recurrence in endometrial cancer with squamous

differentiation may be related to subgroups of its classification. Abeler *et al.* published a cohort with 1985 cases with endometrioid endometrial carcinoma, of which 255 presented squamous differentiation.[12] In this study, the authors divided tumors with squamous differentiation into two groups formerly used: adenoacanthoma (for cytologically well-differentiated squamous differentiation) and adenosquamous carcinoma (for poorly-differentiated squamous differentiation). Five-year overall survival for all patients was 83.5%. Adenoacanthoma subgroup had 91.2% five-year overall survival and adenosquamous subgroup had 64.9%, showing different prognosis.[12]

Molecular analysis with the aim to discover a biomarker that correlates with squamous differentiation in endometrial cancer is even more unclear. Cdx2 is an important gene transcription factor in the carcinogenesis of colorectal cancer.[24] The expression of this biomarker can be present in up to 27% of endometrial cancer but it is never seen in the normal epithelium.[25] Wani *et al.* evaluated Cdx2 expression in endometrial cancer with or without squamous differentiation and the expression of the biomarker was more prevalent in patients with this differentiation.[25] Another biomarker that may be related to squamous differentiation in endometrial cancer is p16, a tumor suppression protein generally expressed in tumors caused by the human papillomavirus (HPV).[26,27]

The strengths of our study include the fact that all patients were treated at the oncogynecology department from a tertiary cancer hospital where protocols are followed closely. The pathology department is also divided into subspecialties, surgical specimens description, sampling and reporting are standardized, resulting in high reproducibility of the pathology reports. Furthermore, the methodology chosen was a well-matched case-control study by age and stage, without differences between groups.

Limitations of this study include its retrospective nature, though our rate of recurrence is consistent with previously published data for low and intermediate-risk stage I tumors.[13] Creasman *et al.* reported a relapse-free survival of 92.3% for surgical patients at five years in stage I.[28] Tumor differentiation grade and endocervical invasion were not statistically significant in the multivariate analysis model, probably due to this limitation. Other obstacles to this study were the fact that it has been carried out in a single institution with possible referral bias and that it did not collect any immunohistochemical data.

In conclusion, this case-control study provides evidence that squamous differentiation in low and intermediate-risk endometrial cancer had a 5.6-fold increased risk for recurrence. This finding demonstrates that more detailed histopathological information could contribute to the analysis of prognosis for the patients.

Supporting information

S1 File. Database case and controls.
(XLSX)

Author Contributions

Conceptualization: Diocesio Alves Pinto de Andrade, Rui Manuel Reis, Ricardo dos Reis.

Data curation: Diocesio Alves Pinto de Andrade, Marcelo de Andrade Vieira, Carlos Eduardo Mattos Cunha Andrade, Ronaldo Luís Schmidt.

Formal analysis: Diocesio Alves Pinto de Andrade, Vinicius Duval da Silva, Graziela de Macedo Matsushita, Marcos Alves de Lima, Rui Manuel Reis, Ricardo dos Reis.

Investigation: Diocesio Alves Pinto de Andrade.

Methodology: Diocesio Alves Pinto de Andrade, Rui Manuel Reis, Ricardo dos Reis.

Project administration: Diocesio Alves Pinto de Andrade, Rui Manuel Reis, Ricardo dos Reis.

Supervision: Rui Manuel Reis, Ricardo dos Reis.

Writing – original draft: Diocesio Alves Pinto de Andrade, Vinicius Duval da Silva, Graziela de Macedo Matsushita, Marcos Alves de Lima, Marcelo de Andrade Vieira, Carlos Eduardo Mattos Cunha Andrade, Ronaldo Luís Schmidt, Rui Manuel Reis, Ricardo dos Reis.

Writing – review & editing: Diocesio Alves Pinto de Andrade, Vinicius Duval da Silva, Graziela de Macedo Matsushita, Marcos Alves de Lima, Marcelo de Andrade Vieira, Carlos Eduardo Mattos Cunha Andrade, Ronaldo Luís Schmidt, Rui Manuel Reis, Ricardo dos Reis.

References

1. Siegel RL, Miller KD, Jemal A. *Cancer statistics*, 2018. 2018; 68(1):7–30.
2. *Estimativa 2018: Incidência de Câncer no Brasil*. [Internet] Rio de Janeiro: INCA–Instituto Nacional de Câncer José Alencar Gomes da Silva; 2018 [cited 10 Ago 2018]; www.inca.gov.br/estimativa/2018/.
3. Bokhman JV. Two pathogenetic types of endometrial carcinoma. *Gynecol Oncol* 1983; 15(1):10–7. [https://doi.org/10.1016/0090-8258\(83\)90111-7](https://doi.org/10.1016/0090-8258(83)90111-7) PMID: 6822361
4. Kitchener H, Swart AM, Qian Q, Amos C, Parmar MK. Efficacy of systematic pelvic lymphadenectomy in endometrial cancer (MRC Astec trial): a randomised study. *Lancet* 2009; 373(9658):125–36. [https://doi.org/10.1016/S0140-6736\(08\)61766-3](https://doi.org/10.1016/S0140-6736(08)61766-3) PMID: 19070889
5. Colombo N, Preti E, Landoni F, Carinelli S, Colombo A, Marini C, et al. Endometrial cancer: ESMO Clinical Practice Guidelines for diagnosis, treatment and follow-up. *Ann Oncol*. 2013; 24 Suppl 6:vi33–8.
6. Creasman WT, Morrow CP, Bundy BN, Homesley HD, Graham JE, Heller PB. Surgical pathologic spread patterns of endometrial cancer. A Gynecologic Oncology Group Study. *Cancer*. 1987; 60(8 Suppl):2035–41. [https://doi.org/10.1002/1097-0142\(19901015\)60:8+<2035::aid-cncr2820601515>3.0.co;2-8](https://doi.org/10.1002/1097-0142(19901015)60:8+<2035::aid-cncr2820601515>3.0.co;2-8) PMID: 3652025
7. dos Reis R, Burzawa JK, Tsunoda AT, Hosaka M, Frumovitz M, Westin SN, et al. Lymphovascular Space Invasion Portends Poor Prognosis in Low-Risk Endometrial Cancer. *Int J Gynecol Cancer*. 2015; 25(7):1292–9. <https://doi.org/10.1097/IGC.0000000000000490> PMID: 26067863
8. AlHilli MM, Mariani A, Bakkum-Gamez JN, Dowdy SC, Weaver AL, Peethambaram PP, et al. Risk-scoring models for individualized prediction of overall survival in low-grade and high-grade endometrial cancer. *Gynecol Oncol*. 2014; 133(3):485–93. <https://doi.org/10.1016/j.ygyno.2014.03.567> PMID: 24690476
9. Zeimet AG, Reimer D, Huszar M, Winterhoff B, Puistola U, Azim SA, et al. L1CAM in early-stage type I endometrial cancer: results of a large multicenter evaluation. *J Natl Cancer Inst*. 2013; 105(15):1142–50. <https://doi.org/10.1093/jnci/djt144> PMID: 23781004
10. Zaino RJ, Kurman RJ. Squamous differentiation in carcinoma of the endometrium: a critical appraisal of adenoacanthoma and adenosquamous carcinoma. *Semin Diagn Pathol*. 1988; 5(2):154–71. PMID: 3041509
11. Kurman RJ, Carcangiu ML, Herrington CS, Young RH. *Tumours of the uterine corpus. WHO Classification of Tumours of Female Reproductive Organs*. 4th Edition ed. Lyon: International Agency for Research on Cancer (IARC); 2014. p. 121–54.
12. Abeler VM, Kjørstad KE. Endometrial adenocarcinoma with squamous cell differentiation. *Cancer*. 1992; 69(2):488–95. [https://doi.org/10.1002/1097-0142\(19920115\)69:2<488::aid-cncr2820690236>3.0.co;2-o](https://doi.org/10.1002/1097-0142(19920115)69:2<488::aid-cncr2820690236>3.0.co;2-o) PMID: 1728379
13. Misirlioglu S, Guzel AB, Gulec UK, Gumurdulu D, Vardar MA. Prognostic factors determining recurrence in early-stage endometrial cancer. *Eur J Gynaecol Oncol*. 2012; 33(6):610–4. PMID: 23327055
14. Zaino RJ, Kurman R, Herbold D, Gliedman J, Bundy BN, Voet R, et al. The significance of squamous differentiation in endometrial carcinoma. Data from a Gynecologic Oncology Group study. *Cancer*. 1991; 68(10):2293–302. [https://doi.org/10.1002/1097-0142\(19911115\)68:10<2293::aid-cncr2820681032>3.0.co;2-v](https://doi.org/10.1002/1097-0142(19911115)68:10<2293::aid-cncr2820681032>3.0.co;2-v) PMID: 1913465
15. Ellenson LH, Ronnett BM, Soslow RA, Zaino RJ, Kurman RJ. Endometrial Carcinoma. In: Kurman RJ, Ellenson LH, Ronnett BM, editors. *Blaustein's Pathology of the Female Genital Tract*. Sixth Edition ed. New York: Springer; 2011. p. 393–452.

16. Harris PA, Taylor R, Thielke R, Payne J, Gonzalez N, Conde JG. Research electronic data capture (REDCap)—a metadata-driven methodology and workflow process for providing translational research informatics support. *J Biomed Inform.* 2009; 42(2):377–81. <https://doi.org/10.1016/j.jbi.2008.08.010> PMID: 18929686
17. Stefansson IM, Salvesen HB, Akslen LA. Loss of p63 and cytokeratin 5/6 expression is associated with more aggressive tumors in endometrial carcinoma patients. *Int J Cancer.* 2006; 118(5):1227–33. <https://doi.org/10.1002/ijc.21415> PMID: 16152605
18. Blanco LZ Jr., Heagley DE, Lee JC, Gown AM, Gattuso P, Rotmensch J, et al. Immunohistochemical characterization of squamous differentiation and morular metaplasia in uterine endometrioid adenocarcinoma. *Int J Gynecol Pathol.* 2013; 32(3):283–92. <https://doi.org/10.1097/PGP.0b013e31826129e1> PMID: 23518912
19. Zaino RJ. FIGO staging of endometrial adenocarcinoma: a critical review and proposal. *Int J Gynecol Pathol.* 2009; 28(1):1–9. <https://doi.org/10.1097/PGP.0b013e3181846c6d> PMID: 19047915
20. Hayes MP, Wang H, Espinal-Witter R, Douglas W, Solomon GJ, Baker SJ, et al. PIK3CA and PTEN mutations in uterine endometrioid carcinoma and complex atypical hyperplasia. *Clin Cancer Res.* 2006; 12(20 Pt 1):5932–5. <https://doi.org/10.1158/1078-0432.CCR-06-1375> PMID: 17062663
21. Jiang W, Chen J, Tao X, Huang F, Zhu M, Wang C, et al. Possible Risk Factors of Pulmonary Metastases in Patients With International Federation of Gynecology and Obstetrics Stage I Endometrioid-Type Endometrial Cancer. *Int J Gynecol Cancer.* 2017; 27(6):1206–15. <https://doi.org/10.1097/IGC.0000000000001002> PMID: 28448305
22. Sturgeon SR, Sherman ME, Kurman RJ, Berman ML, Mortel R, Twiggs LB, et al. Analysis of histopathological features of endometrioid uterine carcinomas and epidemiologic risk factors. *Cancer Epidemiol Biomarkers Prev.* 1998; 7(3):231–5. PMID: 9521439
23. Lax SF, Pizer ES, Ronnett BM, Kurman RJ. Comparison of estrogen and progesterone receptor, Ki-67, and p53 immunoreactivity in uterine endometrioid carcinoma and endometrioid carcinoma with squamous, mucinous, secretory, and ciliated cell differentiation. *Hum Pathol.* 1998; 29(9):924–31. [https://doi.org/10.1016/s0046-8177\(98\)90197-6](https://doi.org/10.1016/s0046-8177(98)90197-6) PMID: 9744308
24. Silberg DG, Swain GP, Suh ER, Traber PG. Cdx1 and cdx2 expression during intestinal development. *Gastroenterology.* 2000; 119(4):961–71. <https://doi.org/10.1053/gast.2000.18142> PMID: 11040183
25. Wani Y, Notohara K, Saegusa M, Tsukayama C. Aberrant Cdx2 expression in endometrial lesions with squamous differentiation: important role of Cdx2 in squamous morula formation. *Hum Pathol.* 2008; 39(7):1072–9. <https://doi.org/10.1016/j.humpath.2007.07.019> PMID: 18495206
26. Caponio MA, Addati T, Popescu O, Petroni S, Rubini V, Centrone M, et al. P16(INK4a) protein expression in endocervical, endometrial and metastatic adenocarcinomas of extra-uterine origin: diagnostic and clinical considerations. *Cancer Biomark.* 2014; 14(2–3):169–75. <https://doi.org/10.3233/CBM-130326> PMID: 24878818
27. Chew I, Post MD, Carinelli SG, Campbell S, Di Y, Soslow RA, et al. p16 expression in squamous and trophoblastic lesions of the upper female genital tract. *Int J Gynecol Pathol.* 2010; 29(6):513–22. <https://doi.org/10.1097/PGP.0b013e3181e2fe70> PMID: 20881863
28. Creasman WT, Odicino F, Maisonneuve P, Quinn MA, Beller U, Benedet JL, et al. Carcinoma of the corpus uteri. FIGO 26th Annual Report on the Results of Treatment in Gynecological Cancer. *Int J Gynaecol Obstet.* 2006; 95 Suppl 1:S105–43.